




Comprehensive Case Analysis of Prostatic Stones: The Role of FTIR Spectroscopy in Biochemical and Chemical Characterization and Management

Abdelaali Ali Belhachem^{1, 2, 3*} , Amina Amiar³, Fatma Boudia^{2, 3}, Mustafa Jamel Yousfi⁴, Houari Toumi^{2, 3}

¹ Pharmaceutical Inorganic Chemistry Laboratory, Faculty of Medicine, University of Oran, Oran, Algeria

² Pharmaceutical Development Research Laboratory, University of Oran, Oran, Algeria

³ Pharmacovigilance Department, University Hospital Establishment of Oran, Oran, Algeria

⁴ Urological Surgery Department, University Hospital Establishment of Oran, Oran, Algeria

ARTICLE INFO

Article Type:

Short Communication

Article History:

Received: 11 Jul 2024

Revised: 18 Nov 2024

Accepted: 25 Nov 2024

Available online: 10 Dec 2024

Keywords:

Biochemical,
Prostate,
Urolithiasis,
Kidney stone,
Infrared spectroscopy

* Corresponding authors:

E-mail: belhachem.ali87@gmail.com

ABSTRACT

Introduction: Bladder stones are a common complication of benign prostatic hyperplasia (BPH), especially in elderly patients with comorbidities, requiring effective management strategies. This report highlights the use of ATR-FTIR spectroscopy in stone composition analysis to guide treatment and prevention.

Methods: This case report describes an 88-year-old male with BPH, arterial hypertension, type 2 diabetes, and chronic renal failure, presenting with pain and urinary retention. His condition was complicated by bladder lithiasis and upper urinary tract involvement, requiring a urinary catheter for four months. Ultrasonography revealed a fully distended bladder with multiple large calculi and a significantly enlarged prostate. The patient underwent upper prostatic adenectomy, during which seven stones (weighing 19.95 g, measuring 1.7-2.2 cm) were extracted and analyzed using optical microscopy and ATR-FTIR spectroscopy.

Results: Microscopic examination revealed smooth, concentric layers with radial crystallization. ATR-FTIR spectroscopy identified uric acid anhydrous as the main component, confirmed by characteristic absorption bands.

Conclusion: This report emphasizes the importance of stone composition in guiding treatment decisions. FTIR spectroscopy offers valuable diagnostic insights and aids in preventing recurrence. Further studies with control groups are necessary to assess long-term outcomes.

Please cite this paper as:

Belhachem AA, Amiar A, Boudia F, Yousfi MJ, Toumi. Comprehensive case analysis of prostatic stones: The role of FTIR spectroscopy in biochemical and chemical characterization and management. Journal of Biochemicals and Phytomedicine. 2024; 3(2): 4-8. doi: 10.34172/jbp.2024.14.

Introduction

Prostatic calculi, also known as prostatic stones, are mineral deposits that can form within the prostate gland. These stones are relatively common, although their exact cause or etiology is not fully understood. They can

vary in size and may be asymptomatic or may cause symptoms such as urinary obstruction, pain, or recurrent urinary tract infections. Treatment options for prostatic calculi range from conservative measures such as

increased fluid intake to more invasive interventions like surgical removal, depending on the size and severity of symptoms (Kalathia et al., 2020).

Giant prostatic urethral calculi are a rare occurrence, with fewer than 20 cases documented in the literature. Furthermore, the simultaneous presence of giant prostatic and bladder calculi is exceedingly uncommon. Prostatic calculi, although relatively rare, still present challenges due to their unclear etiology (Geramoutsos et al., 2004).

A morpho-constitutional analysis of prostate calculi involves examining the physical characteristics and composition of these mineral deposits within the prostate gland. This analysis typically includes techniques such as microscopy, spectroscopy, and imaging to determine the size, shape, colour, and texture of the calculi, as well as the minerals and compounds present in their composition. Understanding the morpho-constitutional properties of prostate calculi can provide valuable insights into their formation mechanisms, potential risk factors, and appropriate treatment strategies. Additionally, it may help clinicians tailor management approaches based on the specific characteristics of the calculi and the individual patient's clinical profile (Belhachem et al., 2023).

The objective of this case report is to analyse the composition of prostatic calculi in an elderly patient with benign prostatic hyperplasia (BPH), complicated by bladder lithiasis and urinary retention, using optical microscopy and ATR-FTIR spectroscopy. The aim is to highlight the clinical relevance of identifying stone composition for optimizing treatment strategies and improving the management of underlying metabolic disorders.

Case report

An 88-year-old male patient with a history of BPH presented with pain and urinary retention. His clinical condition was further complicated by upper urinary tract involvement and the presence of bladder lithiasis. He had been managed with an indwelling urinary catheter for the past four months. The patient's medical history was significant for arterial hypertension, type 2 diabetes mellitus, and chronic renal failure.

Ultrasonographic examination reveals bilateral renal structures exhibiting normal morphology, size, and minimal ureterohydronephrosis, indicative of unremarkable excretory function and favorable corticomedullary differentiation. Notably, the examination also depicts a fully distended bladder characterized by multiple large calculi and a thickened, yet regular, wall. Furthermore, the assessment of the prostate gland discloses a volumetric measurement of 90 milliliters, demonstrating a homogeneous echotexture and the absence of a median lobe. Ultimately, ultrasound findings indicate prostatic hypertrophy complicated by chronic urinary retention, thereby exerting consequential effects on both the upper urinary tract and the development of bladder lithiasis.

The routine blood investigations, including serum biochemistry, were within normal range (urea = 0.39 g/l, creatinine = 10.3 mg/l).

The clinical examination reveals a patient who is cooperative and in overall good health, exhibiting normal skin coloration and conjunctival appearance, with stable hemodynamics. The procedural intervention involved the performance of an upper prostatic adenectomy, coupled with the extraction of stones. Subsequent postoperative care has been supportive, resulting in an outwardly responsive patient status six days following the procedure.

The seven stones that were extracted weighed of 19,95 g and a length range (1.7-2.2 cm) underwent comprehensive analysis and investigation at the pharmacovigilance department of EHU-Oran. Morphological assessment of the stones' surface and cross-sections was conducted utilizing an optical microscope, while their chemical composition was elucidated through spectroscopic ATR-FTIR technique within the range of 450–4000 cm^{-1} (Perkin Elmer) (Figure 1). The microscopic examination revealed a homogeneous, smooth, or slightly embossed surface in ocher or orange brown (Figure 1). The section consists of compact concentric layers with a radiating organization around a well-defined nucleus, forming a concentric structure with radial crystallization.

The FTIR spectrum of the sample showed characteristic absorption bands that are consistent with the presence of uric acid anhydrous. The peaks at 3001.61 cm^{-1} and 2819.76 cm^{-1} correspond to the stretching vibrations of C-H bonds in aliphatic compounds. A strong band at 1661.93 cm^{-1} indicates C=O stretching vibrations, characteristic of carbonyl groups in uric acid, while the peak at 1588.11 cm^{-1} is associated with C=C stretching in the purine ring structure. The absorption bands at 1400.05 cm^{-1} and 1435.68 cm^{-1} are attributed to in-plane bending vibrations of N-H and C-N stretching, further confirming the uric acid structure. Peaks at 1310.95 cm^{-1} and 1348.19 cm^{-1} represent bending and stretching vibrations of N-H groups, while the range from 990.95 cm^{-1} to 1121.77 cm^{-1} highlights C-O and C-N vibrations typical of uric acid derivatives. Furthermore, the bands at 779.16 cm^{-1} , 743.18 cm^{-1} , and 471.97 cm^{-1} correspond to out-of-plane bending vibrations, confirming the crystalline nature of anhydrous uric acid. The presence of these functional groups confirms that the sample is consistent with uric acid anhydrous (C₅H₄N₄O₃), a known constituent of uric acid kidney stones (Figure 2).

Additionally, a fragment of the stone was dissolved to facilitate the examination of its crystal morphology, providing a more comprehensive understanding of the stone's characteristics and composition. The analysis revealed that the crystals appear as rhomboid or diamond-shaped structures with smooth edges.

The active compounds chosen for stone composition analysis were identified based on their roles in metabolic pathways linked to stone formation, such as uric acid and calcium metabolism. The selection criteria emphasized bioavailability, prioritizing compounds with high urinary bioavailability to ensure their potential contribution to prostatic stone formation. Furthermore, compounds with known pharmacological activity in metabolic disorders like hyperuricemia and diabetes, which are commonly associated with stone development, were included. For instance, uric acid and its derivatives were selected due to their strong correlation with metabolic syndrome and their role in stone formation.

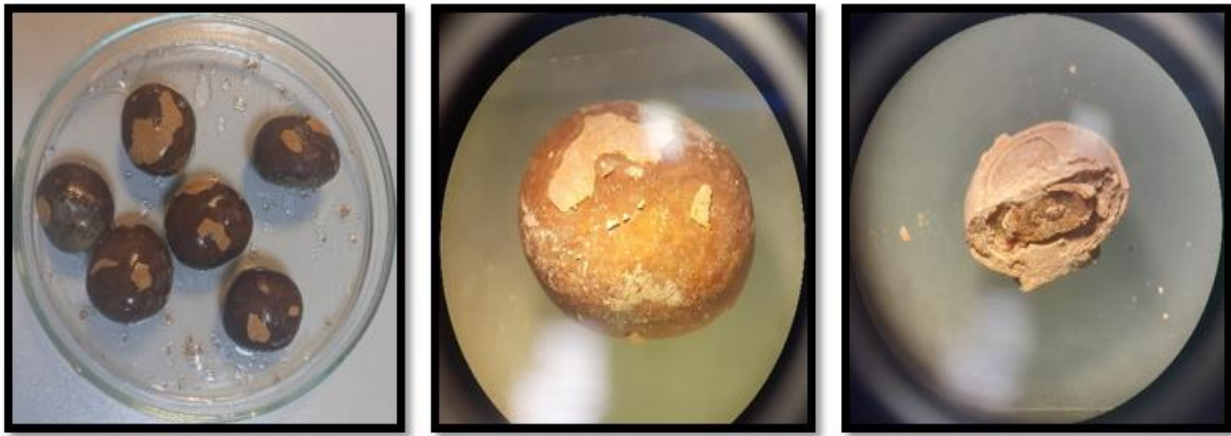


Figure 1. Microscopic view of prostatic stones. The stones show homogeneous, smooth, or slightly embossed surface in other, orange brown.

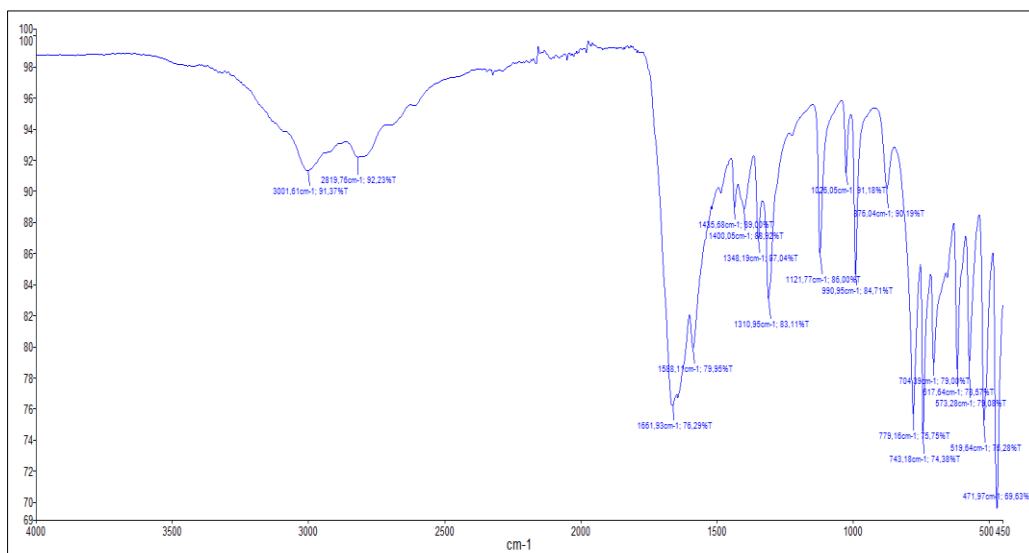


Figure 2. FTIR spectrum of the prostatic stone. It shows characteristic absorption bands for uric acid anhydrous

Discussion

Prostatic calculi, or prostate stones, are relatively common and often found incidentally in older men during imaging or surgery for other urological conditions. These stones can contribute to symptoms such as lower urinary tract symptoms (LUTS), prostatitis, and chronic pelvic pain syndrome (CPPS). Understanding the composition of prostatic calculi is crucial for diagnosing underlying metabolic disorders, guiding treatment, and preventing recurrence. Prostatic urethral stones can be categorized into two main types: endogenous (primary) and exogenous (secondary). Primary stones are typically small and numerous, forming *de novo* due to the precipitation of substances in prostatic secretions as a result of obstructions, inflammation, and chronic infection in the prostatic ducts. In contrast, secondary stones, which are larger, form in the upper tract and migrate downwards (Kalathia et al., 2020).

The exact prevalence of prostatic calculi is not well-established, with reports ranging from 7% to 70%. Most prostatic calculi cases are asymptomatic and are typically discovered incidentally during the diagnosis of BPH via transrectal ultrasonography (TRUS). However,

prostatic calculi associated with chronic prostatitis may cause chronic pelvic pain. Rarely, large extrinsic prostatic calculi caused by urine reflux can lead to voiding difficulties. Over 80% of prostatic calculi are composed of calcium phosphate (Kalathia et al., 2020). Long-term, the presence of prostatic calcifications can also increase the risk of chronic bacterial colonization, which can complicate the clinical course of BPH or prostatitis. Additionally, these calcifications may interfere with effective treatment, as they can act as a nidus for recurrent infections and stone formation. Understanding the underlying causes and composition of these calcifications is essential for guiding appropriate management strategies and preventing long-term complications (Madersbacher et al., 2019).

Klimas et al. proposed that prostatic secretions, corpora amylacea, or inflammation can block the secretory ducts, leading to thickening and calcification of stones (Klimas et al., 1985). These stones typically form as multiple small stones, and represent a pathophysiological phenomenon associated with aging, primarily occurring after age 50 years. Additionally, Kirby et al. hypothesized that prostatic hypertrophy

leads to chronic prostate inflammation, which in turn contributes to the formation of calculi (Kirby et al., 1982). In this case, however, the stone consisted of anhydrous uric acid, often associated with dietary habits, dehydration, or genetic predisposition. These stones are more likely to precipitate in acidic urine, where their solubility decreases (Kenny and Goldfarb, 2010). Uric acid stones are less common in the prostate compared to the kidneys, but they can still occur under certain conditions. The formation of uric acid stones in the prostate can be influenced by several factors. Metabolic syndrome, including conditions such as obesity, diabetes, and hyperuricemia, increases the risk by leading to acidic urine that promotes uric acid crystallization. High-purine diets, rich in red meat, shellfish, and alcohol, elevate uric acid levels in the body and urine, facilitating stone formation (Zhang et al., 2022).

Detecting uric acid in prostate stones can lead to a metabolic evaluation to address conditions like hyperuricemia or metabolic syndrome, with treatments such as allopurinol or febuxostat to control uric acid levels and urine alkalization to dissolve existing stones and prevent new ones (Jahrreiss et al., 2024). Preventive measures include dietary changes to reduce purine intake, increased hydration, and maintaining an alkaline urine pH. Additionally, managing these metabolic issues can help alleviate symptoms associated with prostatic calculi, such as lower urinary tract symptoms (LUTS), chronic pelvic pain, and prostatitis (Nimbalkar et al., 2021).

Conclusions

FTIR spectroscopy is an essential tool for analyzing prostatic stones, providing detailed insights into their chemical composition. By identifying the specific minerals present in these stones, this technique aids in guiding clinical management decisions, including diagnosis, treatment options, and preventive strategies. Continued research leveraging advanced spectroscopic methods is crucial for deepening our understanding of prostatic calculi and improving patient outcomes. Studies have demonstrated the effectiveness of allopurinol in managing uric acid stones, emphasizing its potential to significantly reduce recurrence rates. Additionally, the role of dietary modifications and increased hydration has been highlighted as effective strategies for preventing stone formation, particularly in patients with metabolic syndrome. These findings underscore the importance of tailored management approaches that combine pharmacological treatments with lifestyle interventions to optimize patient outcomes.

Declarations

Conflict of interest

The authors declare that they have no competing interests.

Acknowledgement

Authors would like to thank the team of Pharmacovigilance and Urological surgery departments of EHU-ORAN, and the pharmaceutical development research laboratory, University Oran 1-Algeria.

Consent for publications

All authors read and approved the final manuscript.

Funding/support

No funding was obtained for this research.

Authors' contributions

AAB and AA carried out the study, designed and conducted all laboratory analyses, interpreted experimental results, and prepared the manuscript. HT, MJY and FB supervised the study.

Ethical considerations

According to Algerian regulations, seeking approval from an ethics committee is not required for case reports or non-interventional studies. Since this kidney stone analysis utilized previously collected, anonymized clinical data, ethical approval and consent to participate were not necessary. Research that involves analyzing pre-existing, de-identified data without any direct interaction with or intervention involving patients does not mandate ethical approval. In addition, during the preparation of this work, the authors used OpenAI's language model (Chat GPT and WordVice) in order to enhance the clarity and coherence of the manuscript. After using this tool, the authors reviewed and edited the content as needed and takes full responsibility for the content of the publication.

References

- Belhachem A, Toumi H, Yousfi MJ. Handbook of Urolithiasis Classification. Lambert Academic Publishing, Saarbrücken, Germany; 2023. ISBN: 978-620-7-45426-6.
- Geramoutsos I, Gyftopoulos K, Perimenis P, Thanou V, Liagka D, Siambli D, et al. Clinical correlation of prostatic lithiasis with chronic pelvic pain syndromes in young adults. *European Urology*. 2004;45(3):333–7. DOI: 10.1016/j.eururo.2003.09.020.
- Jahrreiss V, Seitz C, Quhal F. Medical management of urolithiasis: Great efforts and limited progress. *Asian J Urol*. 2024;11(2):149-155. doi: 10.1016/j.ajur.2023.05.001.
- Kalathia J, Patel K, Agrawal S. Giant prostatic and bladder calculi: Endoscopic management and review of the literature. *Urology Case Reports*. 2020;35:101529. doi: 10.1016/j.eucr.2020.101529.
- Kenny JE, Goldfarb DS. Update on the pathophysiology and management of uric acid renal stones. *Current Rheumatology Reports*. 2010;12(2):125-129. doi:10.1007/s11926-010-0089-y
- Kirby RS, Lowe D, Bultitude MI, Shuttleworth KE. Intra-prostatic urinary reflux: an aetiological factor in abacterial prostatitis. *British Journal of Urology*. 1982;54(6):729-731. doi:10.1111/j.1464-410x.1982.tb13635.x
- Klimas R, Bennett B, Gardner WA Jr. Prostatic calculi: a review. *Prostate*. 1985;7(1):91-96. doi:10.1002/pros.2990070110
- Madersbacher S, Sampson N, Culig Z. Pathophysiology of benign prostatic hyperplasia and benign prostatic

enlargement: A mini-review. *Gerontology*. 2019;65(5):458-464. doi:10.1159/000496289

Nimbalkar A, More V, Mehta S. Multiple Large Prostatic Stones Causing Chronic Pelvic Pain: A Case Report. *Cureus*. 2021;13(12):e20583. doi:10.7759/cureus.20583.

Zhang Y, Chen S, Yuan M, Xu Y, Xu H. Gout and Diet: A Comprehensive Review of Mechanisms and Management. *Nutrients*. 2022;14(17):3525. doi:10.3390/nu14173525.

Copyright © 2024 The Author(s). This is an open-access article distributed under the terms of the Creative Commons Attribution License (<http://creativecommons.org/licenses/by/4.0>), which permits unrestricted use, distribution, and reproduction in any medium, provided the original work is properly cited.